13th Batch

Exam Committee

NEU 241 Final SAQ

Disclaimer: **3 of the 4 scenarios were collected; the last one was about the cerebellar functions + disorders but no one could remember any of it for the life of them (I asked 10 different people). The SAQ was phrased a bit weirdly as compared to this document and was not as clear, so be prepared for that. Good luck and I wish you all the best <3**

- **Khaled H.**

For any inquiries, don't hesitate to contact me on email: khamsho@alfaisal.edu

NEU 241 SAQ

1. A 14-year old with poor performance in school has episodes of "staring off". After seeing the physician, he was started on a medication called ethosuximide
   A. What is the difference between epilepsy and seizure?
   B. Give 2 examples of epilepsy with their clinical presentation*
   C. Why is the patient experiencing episodes of "staring off"?
   D. What is the mechanism of action of ethosuximide and how was it useful in this case?

Answers:

A. Seizure: abnormal hyperactivity & overactivation of neurons; epilepsy is condition in which patients experience multiple seizures
B. **question was appealed and descriptions of seizures were considered correct:*
   Absence seizures → Young patient experiencing very brief and temporary loss of consciousness without any post-ictal confusion
   Generalized tonic-clonic seizure → 2 phases: 1. Tonic: patient loses consciousness and falls down, their body would be stiff and rigid. 2. Clonic → classical jerking movements of all limbs

C. "Staring off" is characteristic of absence seizures where the patient experiences a very brief loss of consciousness which appears from the outside as if the patient was lost in thought staring off in a distance

D. Ethosuximide inhibits T-Type calcium channels in the thalamus and therefore prevents the onset of absence seizures

2. A 43-year-old woman is brought to the ER because of a sudden and severe headache (worst headache of her life). Her BP is 160/90mm Hg and pulse is 90/min. Her pupils are symmetric and reactive to light, and she can move all four limbs without weakness. A CT of the head is shown below:

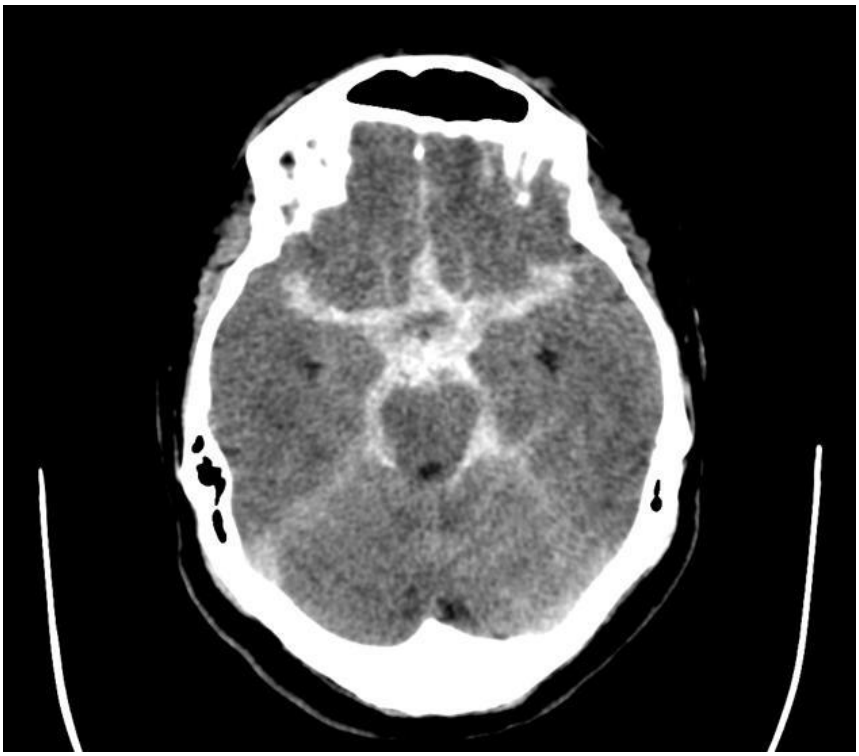

A. List the components of the circle of Wilis
B. What is the cause of this presentation of the patient?
C. Discuss the different types of intra-cranial hemorrhages based on their clinical presentation

Answers:

A. Acom, Pcom, internal carotid, ACA, PCA
B. Rupture of Saccular aneurysm
C. 1. Epidural hemorrhage: rupture of middle meningeal artery. Patient experiences lucid interval and the hemorrhage has a biconvex appearance on CT 2. Subdural hemorrhage: rupture of bridging veins. Crescent shaped hemorrhage on CT. Seen in elderly patient after experiencing trauma in the head: CHRONIC PRESENTATION: weeks until symptoms appear 3. Subarachnoid hemorrhage: star-shaped hemorrhage on CT; usually due to rupture of saccular aneurysm; patient presents with worst headache of their life; usually spontaneous. 4. Intraparenchymal hemorrhage: usually due to rupture of Charcot Bouchard micro aneurysm secondary to hypertension, patient presents with focal neurological deficits depending on site of hemorrhage. Hemorrhage most commonly in the basal ganglia, especially the putamen

3. The following image shows different brain waves obtained from an EEG. Use the image to answer the questions:

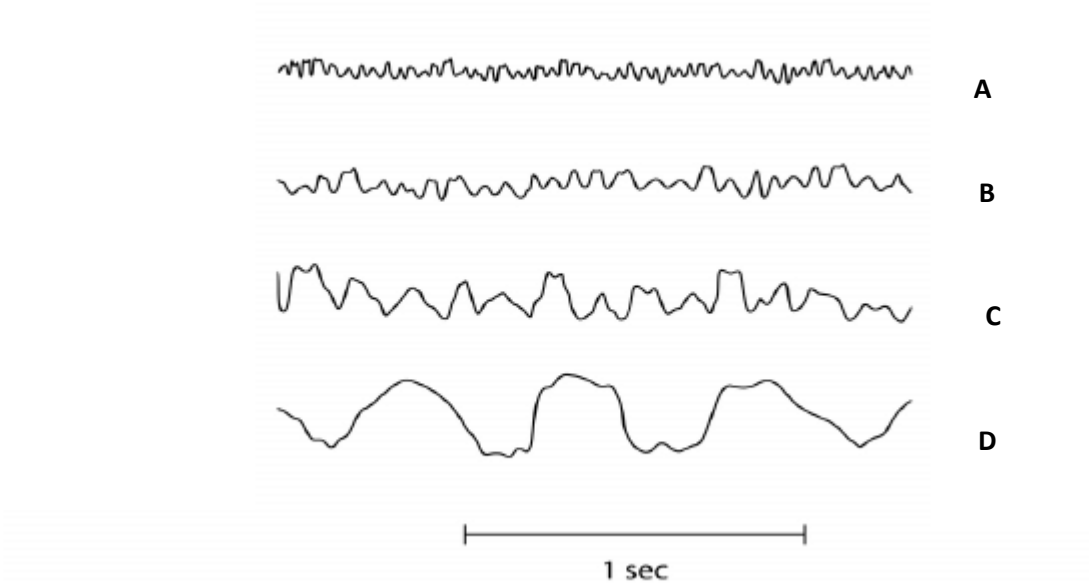

A. In the first diagram, which of the following shows the EEG wave form during REM sleep (mention its name as well)
B. In the first diagram, which of the following EEG wave forms is normal in infants who are awake but indicates a pathology in adults who are awake; mention its name as well?
C. In the first diagram, which of the following EEG wave forms is seen in adults who are awake with their eyes closed; mention its name as well?
D. In the second diagram, the patient was asked to close his eyes. After some time, he was asked to perform some mental math. At which of the following points indicates the start of this mental activity?

Answers:

A. A; beta wave
B. D; delta wave
C. B; Alpha wave
D. Point A